

A 2 year child presenting with Cryptogenic Cerebral Abscess: A Case report

Dr. Madoori Srinivas¹, Dr. Ramya. C², Dr. Dikshitha³, Dr. Praneet. N³

¹Professor, ²Associate Professor, ³Post graduate student

Department of Pediatrics, Chalmeda anand rao institute of medical sciences and hospital, Karimnagar

Abstract: Brain abscess is an intracranial suppurative infection in young children, usually with underlying infection or predisposing factors. Commonly seen in neonates and children between 4-8 years age. It is caused by extension from sinusitis, orbital cellulitis, chronic suppurative otitis media, mastoiditis, congenital heart disease, soft tissue infection of face and scalp, dental infections complicated pneumonia immunodeficiency states, infection of ventriculoperitoneal shunts and penetrating injuries. Mortality is high, upto 60%, if not diagnosed early and treated immediately. We report a 21 months old girl who presented with cryptogenic cerebral abscess.

Keywords: Brain abscess, children, cryptogenic.

I. Introduction

Brain abscess can occur in children of any age group mostly between ages of 4-8 years and in neonates⁽¹⁾. It is a dynamic focal infection within the brain parenchyma which begins as a localised area of cerebritis and evolves into a collection of pus within a well vascularised capsule⁽²⁾. Hospital based studies from india report an average incidence of 8-15 cases/year⁽²⁾. Brain abscess account for 8% of intracranial masses in developing countries and 1-2% in developed countries. Paediatric cases constitute almost 25-42% of all brain abscess⁽²⁾. Most brain abscess are single but 30% are multiple and may involve more than one lobe⁽¹⁾. Brain abscess in the occipital lobe, cerebellum and brainstem account for approximately 20% of the cases⁽¹⁾. The signs and symptoms of brain abscess are non specific at the onset. The classical triad of fever, headache and focal neurological signs is rare. Fever may be present only in 60-80% cases, headache in 50-80%, vomiting in 20-70%, focal deficits in 35-50% and seizures in 20-25% and therefore, its absence should not exclude the diagnosis⁽¹⁾. Broadly, the clinical features results from any of the four clinical syndromes namely focal mass expansion, intracranial hypertension, diffuse destruction and focal neurological deficits⁽²⁾. As the abscess evolves surrounding vasogenic edema increases and results in midline shift and worsening signs of raised intracranial pressure and impending herniation. If the abscess ruptures into the ventricular cavity, overwhelming shock and death usually ensue⁽²⁾.

II. Case Report

A 21 months old female child presented with fever for 2 days and vomiting for 1 day and 1 episode of seizure. Child presented with fever, high grade, intermittent, not associated with chills and rigors; vomiting, 2-3 episodes non projectile, non bilious, containing food particles and 1 episode of generalised tonic clonic seizure, lasting for 5 mins associated with deviation of angle of mouth, uprolling of eye ball, drooling of saliva and loss of consciousness for 10 mins. There was no postictal amnesia. There was no history of sinusitis, ear discharge or any head injury. The child was born to non consanguineous parents. Father had history of febrile seizures during childhood and was on antiepileptics for 5 years. She was born at full term through LSCS without any perinatal problems. Child was immunized till date. The neuropsychomotor development of the child was normal.

On examination child was drowsy at presentation. Child falls between 3rd and 50th percentile weight for age and is 50th percentile height for age. The vitals were normal. On neurological examination power was grade 5 and tone was normal in all 4 limbs, reflexes were normal and there was no signs of meningeal irritation.

Lumbar puncture was done to rule out CNS infection and was found to be normal. Fundus examination was normal. Child was treated as febrile seizures initially for 2 days. After 2 days child developed head lag and 3 episodes of vomiting. CT scan of Brain was done which showed 37 x 40 mm sized cerebral abscess in left temporoparietal region with perilesional edema causing mass effect and midline shift(Fig 1). The 2D Echo was done to rule out underlying congenital heart disease, which was normal.

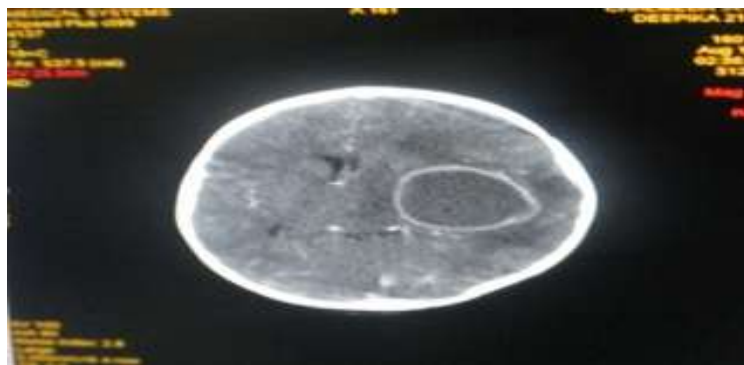


Fig 1

The child was taken up for an emergency surgery to excise the abscess. Left fronto parietal decompressive craniotomy and excision of brain abscess was done under general anaesthesia. Abscess with thick capsule was seen and thick greenish yellow pus was drained and sent for culture. The thick capsule was removed(Fig 2 and 3).

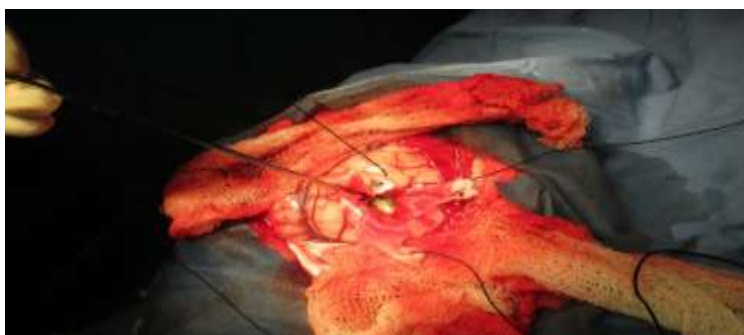

Fig 2:

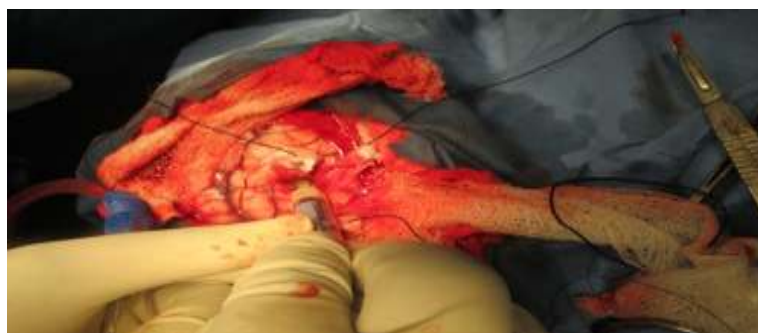

Fig 3:

Child was stable throughout the postoperative period. Child was started on Meropenem, Vancomycin, Metrogyl and prophylactic antiepileptic, Phenytoin sodium. The repeat CT scan after 3 days showed minimal edema. Child was discharged after full antibiotic course. On followup, child was normal without any neurological deficit.

III. Discussion

Brain abscess is a suppurative infection. Paediatric abscess are supratentorial in 85%, infratentorial in 13% and combined in 2% cases⁽¹⁾. In our case, the child is 21 months old. The brain abscess is not common in this age, while the most common age group being 4-8 years and neonates⁽¹⁾. There are 4 stages of abscess formation early cerebritis, late cerebritis, early capsulation and late capsulation⁽²⁾. The capsule of the abscess is thickest towards the meninges and thinnest towards the ventricular ends⁽²⁾. The clinical features are based on the specific cerebral region involved⁽²⁾. In the present case the child had a thick capsule which was removed during the surgery.

The clinical features vary according to the lobe involved. If the frontal lobe is involved the abscess is initially silent, then drowsiness, personality changes, seizures, appearance of primitive reflexes and hemiparesis

may appear. If the parietal lobe is involved there is visual field defects like inferior quadrantanopia to homonymous hemianopia. If the dominant hemisphere is involved dysphagia and if non dominant hemisphere is involved dyspraxia and spatial neglect are seen. If the temporal lobe is involved dysphasias are seen if dominant hemisphere is involved and quadrantanopsia is seen if non dominant hemisphere is involved. If the occipital lobe is involved it ruptures into ventricle causing ventriculitis/ependymitis, septic thrombophlebitis of the transverse sinus. If the cerebellum is involved appendicular and gait ataxias, eye movement abnormalities are seen. If the brainstem is involved obstructive hydrocephalous, multiple cranial nerve palsies are seen. In our case the abscess was present in the temporoparietal region. But the child did not develop any dysphagia, dyspnea or visual field defects.

The child had one episode of seizures which is common if frontal lobe is involved. Seizures can be the initial manifestation of brain abscess in upto 25-43% of cases⁽⁸⁾. Antiepileptics are required for children who develop seizures for 1-4 months⁽²⁾. In the case of children, anticonvulsants are recommended in those who have developed seizures to potentially prevent further episodes. The duration should be individualised and guided by EEG studies in the follow up phase of disease. Most authors recommend providing atleast 3 months of prophylaxis if no more seizures have occurred⁽⁹⁾. We have put the child on phenytoin to prevent the seizures.

The causative organisms are aerobic and anaerobic streptococci with streptococcus milleri group (streptococcus anginosus, streptococcus constellatus and streptococcus intermedius), streptococcus pneumonia, group A, B streptococci, enterococcus faecalis, Bacteroid species, Fusobacterium species, Prevotella species, Actinomyces species, Haemophilus aphrophilus, haemophilus parainfluenza, Haemophilus influenza, E.coli, Proteus species, mycobacterium species, listeria species Fungi like aspergillus and candida⁽¹⁾. Anaerobic isolates include Bacteroid species (Bacteroid fragilis) and anaerobic streptococci (Peptostreptococcus)⁽⁸⁾. The finding of sterile brain abscess was serious diagnostic dilemma to neurosurgeon until Ingham et al(1977) introduced the routine anaerobic culture technique with anaerobic organisms as causative factors⁽³⁾. In our case culture was sterile and the causative organism is not known.

Approximately 80% of patients with brain abscess have a known predisposing factor while remaining 20% are cryptogenic⁽⁴⁾. The main route of infection are contiguous spread (25-50%) is usually single involves spread of infection from pericranial non neural contiguous focus such as the sinuses, middle ear, dental infection or inflamed meninges as a complication of meningitis. Hematogenous spread (15-30%) is usually multiple involves spread from distant focus like in congenital heart disease, bacterial endocarditis, empyema, skin and intra abdomen. Direct inoculation(8-15%) secondary to compound skull fractures, scalp wounds anterior cranial fossa or temporal bone fractures, chronic cerebrospinal fluid fistula and neuro surgical procedures⁽²⁾. Our child did not have any predisposing factors like otitis media, sinusitis, mastoiditis, congenital cerebral disease etc. The echo was also normal. Cryptogenic cerebral abscess is generally rare in children.

CT Brain finding of cerebritis in early stages are characterised by a parenchymal low density lesion⁽¹⁾. In later stages the typical finding is a hypodense lesion with thin uniform ring enhancement on contrast CT imaging. MRI Brain with gadolinium on T1 weighted images brain abscess appears as a hypointense lesion with ring enhancement. On T2 weighted images it appears as a central hyperintense lesion encircled by a uniform hypointense capsule and surrounded by an irregular hyperintense area of perilesional edema⁽²⁾.

Treatment of choice is mainly third generation cephalosporins, vancomycin and Metronidazole. The duration of antibiotic therapy depends on the organism and response to treatment but usually for 4-6 weeks⁽¹⁾. From the studies about 60% of children may have neurological and developmental sequelae^(5,7). The commonest problems reported are hemiparesis, seizures, visual field defects, and learning difficulties^(6,7). Repeat MRI scan or CT scan of Brain after 2-4 weeks to document the resolution⁽²⁾. Surgery is needed if the abscess is >2.5cm in diameter, gas is present in the abscess, multiloculated, lesion located in the posterior fossa or fungus is identified⁽¹⁾. The duration of antibiotic therapy depends on the organism and response to treatment but usually for 4-6 weeks⁽¹⁾. As the abscess was large surgical excision was done immediately and the thick capsule was removed along with the drainage of the abscess. The child was on vancomycin for 4 weeks and metronidazole for 3 weeks. The repeat CT scan of Brain after 2 weeks showed minimal oedema and the child improved and was discharged on Phenytoin.

Prognosis is 3-25% with the wider use of CT and MRI of Brain, improved microbiologic techniques and prompt antibiotic and surgical management. Mortality is higher in younger age less than 1 year, multiple abscesses and coma⁽¹⁾.

IV. Conclusion

Brain abscess can present in any form so high index of suspicion must be excised as it may lead to mortality if not diagnosed early. Cryptogenic brain abscess is rare in children hence we are reporting this case.

Acknowledgement

We would like to thank Dr. PVK. Kishore, Neurosurgeon for his timely intervention, Mr. C Lakshminarasimha Rao, chairman and Dr. V Suryanarayan Reddy, Director, CAIMS, Karimnagar for giving permission to publish the case, and Mr. Ramesh, Stenographer, Pediatric department for his valuable help.

Conflict of interest: Nil.

Source of funding: Nil

References

- [1]. Charles G, Prober and rubhni Mathew. Brain abscess. Nelson text book of paediatrics. 20th edition. 2015; 2949-2950.
- [2]. Prashant Jauhari, Jitendra kumar Sahu. Brain Abscess. Brain Abscess. PG text book of pediatrics by Piyush Gupta. 2015; 2160-2172.
- [3]. Rosenblum ML, Mampalan TJ, PonsVG. controversies in the manangement of brain abscess clinical neurosurgery. 1986; 33: 603-632.
- [4]. Ingham HR, Selka JB, Roxby CM. Bacteriological study of autogenic cerebral abscess: Chemotherapeutic role of metronidazole. Br.MedJ. 1977;2:991.
- [5]. Idriss ZA, Gutman LT,Knonfol NM. Brain abscess in infants and children-current status of clinical findings, management and prognosis. Clinic paediatr (Phila). 1978; 738-746.
- [6]. Hoffman HJ, Hendrick EB, Hiscox JL. Cerebral abscesses in early infancy. J neurosurgery. 1970; 33: 172-177.
- [7]. Carey ME, Chou SN, French LA. Long term neurological residual in patients surviving brain abscess with surgery. J neurosurg. 1971; 34: 652-656.
- [8]. De Louvois, Gortvai P, Hurley R. Bacteriology of abscesses of CNS, a multicentric prospective study. Br Med J(clin res). 1977; 2: 981-984.
- [9]. Saez Llorens X. Brain abscess in children. Semin paediatr infect Dis. 2003; 108-114.